

# Managing Incidental Findings on Thoracic CT: Lung Findings. A White Paper of the ACR Incidental Findings Committee

SA-CME

Editor's Choice

Reginald F. Munden MD DMD MBA<sup>a b</sup> William C. Black MD<sup>c d</sup> Thomas E. Hartman MD<sup>e</sup> Heber MacMahon MB BCh<sup>f</sup> Jane P. Ko MD<sup>g h</sup> Debra S. Dyer MD<sup>i j</sup> David Naidich MD<sup>k l</sup> Santiago E. Rossi MD<sup>m n</sup> H. Page McAdams MD<sup>o</sup> Eric M. Goodman MD<sup>p q</sup> Kathleen Brown MD<sup>r s t</sup> Michael Kent MD<sup>u v</sup> Brett W. Carter MD<sup>w x y</sup> Caroline Chiles MD<sup>z</sup> Ann N. Leung MD<sup>aa bb cc</sup> Phillip M. Boiselle MD<sup>dd ee</sup> Ella A. Kazerooni MD<sup>ff</sup> Lincoln L. Berland MD<sup>gg</sup> Pari V. Pandharipande MD MPH<sup>hh ii jj kk</sup>

Credits awarded for this enduring activity are designated “SA-CME” by the American Board of Radiology (ABR) and qualify toward fulfilling requirements for Maintenance of Certification (MOC) Part II: Lifelong Learning and Self-assessment. To access the SA-CME activity visit [https://cortex.acr.org/Presenters/CaseScript/CaseView?Info=2bqS6\\_2fPz\\_2bbXvo1pI5OZ\\_2fJpg8ZISPW\\_2f\\_zYdxKpJhNos\\_253d](https://cortex.acr.org/Presenters/CaseScript/CaseView?Info=2bqS6_2fPz_2bbXvo1pI5OZ_2fJpg8ZISPW_2f_zYdxKpJhNos_253d). SA-CME credit for this article expires August 31, 2024.

## Abstract

The ACR Incidental Findings Committee presents recommendations for managing incidentally detected lung findings on thoracic CT. The Chest Subcommittee is composed of thoracic radiologists who endorsed and developed the provided guidance. These recommendations represent a combination of current published evidence and expert opinion and were finalized by informal iterative consensus. The recommendations address commonly encountered incidental findings in the lungs and are not intended to be a comprehensive review of all pulmonary incidental findings. The goal is to improve the quality of care by providing guidance on management of incidentally detected thoracic findings.

**Key Words:** Incidental, interstitial lung abnormalities, lung cysts, pulmonary nodule

J Am Coll Radiol 2021;18:1267-1279. Copyright © 2021 American College of Radiology

<sup>a</sup>Professor, Department of Radiology and Radiological Sciences, Medical University of South Carolina, Charleston, South Carolina.

<sup>b</sup>Chair, Department of Radiology and Radiological Sciences, Medical University of South Carolina, Charleston, South Carolina.

<sup>c</sup>Professor of Radiology, Emeritus, Geisel School of Medicine at Dartmouth, Lebanon, New Hampshire.

<sup>d</sup>Dartmouth-Hitchcock Medical Center, Lebanon, New Hampshire.

<sup>e</sup>Professor of Radiology, Mayo Clinic, Rochester, Minnesota.

<sup>f</sup>Professor of Radiology, Section of Thoracic Imaging, Department of Radiology, The University of Chicago, Chicago, Illinois.

<sup>g</sup>Professor of Radiology, Department of Radiology, NYU Langone Health, New York, New York.

<sup>h</sup>Fellowship Director, Cardiothoracic Imaging, Department of Radiology, NYU Langone Health, New York, New York.

<sup>i</sup>Professor, Department of Radiology, National Jewish Health, Denver, Colorado.

<sup>j</sup>Chair, Department of Radiology, National Jewish Health, Denver, Colorado.

<sup>k</sup>Professor, Emeritus, NYU-Langone Health, New York, New York.

<sup>l</sup>Department of Radiology, NYU Grossman School of Medicine, New York, New York.

<sup>m</sup>Chairman, Centro Rossi, Buenos Aires, Argentina.

<sup>n</sup>Chest Section Head, Hospital Cetrángolo, Buenos Aires, Argentina.

<sup>o</sup>Professor of Radiology, Duke University Health System, Durham, North Carolina.

<sup>p</sup>Assistant Professor, Department of Radiology, Zucker School of Medicine at Hofstra/Northwell, Manhasset, New York.

<sup>q</sup>Associate Program Director, Diagnostic Radiology, Department of Radiology, Zucker School of Medicine at Hofstra/Northwell, Manhasset, New York.

<sup>r</sup>Professor, Department of Radiology, David Geffen School of Medicine at UCLA, Los Angeles, California.

<sup>s</sup>Section Chief, Thoracic Imaging, Department of Radiology, David Geffen School of Medicine at UCLA, Los Angeles, California.

<sup>t</sup>Assistant Dean, Equity and Diversity Inclusion, David Geffen School of Medicine at UCLA, Los Angeles, California.

<sup>u</sup>Associate Professor of Surgery, Harvard Medical School, Boston, Massachusetts.

## OVERVIEW OF THE ACR INCIDENTAL FINDINGS PROJECT

The core objectives of the Incidental Findings Project are to (1) develop consensus on patient characteristics and imaging features that are required to characterize an incidental finding; (2) provide guidance to manage such findings in ways that balance the risks and benefits to patients; (3) recommend reporting terms that reflect the level of confidence regarding a finding; and (4) focus future research by proposing a generalizable management framework across practice settings.

## THE CONSENSUS PROCESS: MANAGEMENT OF INCIDENTAL LUNG FINDINGS

This article presents the recommendations from the Incidental Findings Committee (IFC) regarding incidental lung findings detected on thoracic CT. The publication is divided into two parts: (1) lung nodules and (2) other lung findings. The process of developing these recommendations included naming an overall Chest Subcommittee chair, who appointed Subcommittee members that are recognized experts in thoracic imaging. The scope of incidental thoracic findings was recognized to be large. Therefore, within the Chest Subcommittee, four further subgroups were named (here termed “System Subcommittees”) and tasked with addressing each of four categories: lung nodules, other lung findings, the

mediastinum, and the cardiovascular system. A white paper that addresses incidental mediastinal and cardiovascular findings has been published [1]. This current white paper addresses lung nodules and other lung findings (cysts, ground glass opacities, and interstitial findings). The membership of each System Subcommittee is listed in the e-only Appendix.

Each System Subcommittee was tasked to define incidental findings that were most important to address and to develop corresponding recommendations. Published evidence was used as the primary resource; if evidence was not available, the System Subcommittees invoked the collective expertise of their teams. Recommendations underwent further review by the System Subcommittee chairs, the chair of the overall Chest Subcommittee, the chair of the IFC, and the Body Commission chair. The revised recommendations were then submitted to additional ACR stakeholders to gain input and feedback. Consensus was obtained iteratively after successive reviews and revisions.

After completion of this process, the white papers were finalized. The IFC’s consensus processes meet policy standards of the ACR. However, they do not meet any specific, formal national standards. The recommendations do not represent policy of the ACR Practice Guidelines or the ACR Appropriateness Criteria. Our consensus may be termed “guidance” and “recommendations” rather than “guidelines,” which has a more formal definition [2].

<sup>v</sup>Director, Minimally Invasive Thoracic Surgery, Division of Thoracic Surgery and Interventional Pulmonology, Beth Israel Deaconess Medical Center, Boston, Massachusetts.

<sup>w</sup>Associate Professor, Department of Thoracic Imaging, University of Texas MD Anderson Cancer Center, Houston, Texas.

<sup>x</sup>Director of Clinical Operations, University of Texas MD Anderson Cancer Center, Houston, Texas.

<sup>y</sup>Chief Patient Safety and Quality Officer, Diagnostic Imaging, University of Texas MD Anderson Cancer Center, Houston, Texas.

<sup>z</sup>Professor, Department of Radiology, Wake Forest Baptist Health, Winston Salem, North Carolina.

<sup>aa</sup>Professor, Clinical Affairs, Stanford University Medical Center, Stanford, California.

<sup>bb</sup>Associate Chair, Clinical Affairs, Stanford University Medical Center, Stanford, California.

<sup>cc</sup>Department of Radiology, Stanford University Medical Center, Stanford, California.

<sup>dd</sup>Professor, Quinnipiac’s Frank H. Netter MD School of Medicine, North Haven, Connecticut.

<sup>ee</sup>Dean, Quinnipiac’s Frank H. Netter MD School of Medicine, William and Barbara Weldon Dean’s Chair of Medicine, North Haven, Connecticut.

<sup>ff</sup>Professor of Radiology, Division of Cardiothoracic Radiology and Internal Medicine, Division of Pulmonary and Critical Care Medicine, University of Michigan Medical School, Ann Arbor, Michigan.

<sup>gg</sup>Professor Emeritus, University of Alabama at Birmingham, Birmingham, Alabama.

<sup>hh</sup>Director, MGH Institute for Technology Assessment, Massachusetts General Hospital, Boston, Massachusetts.

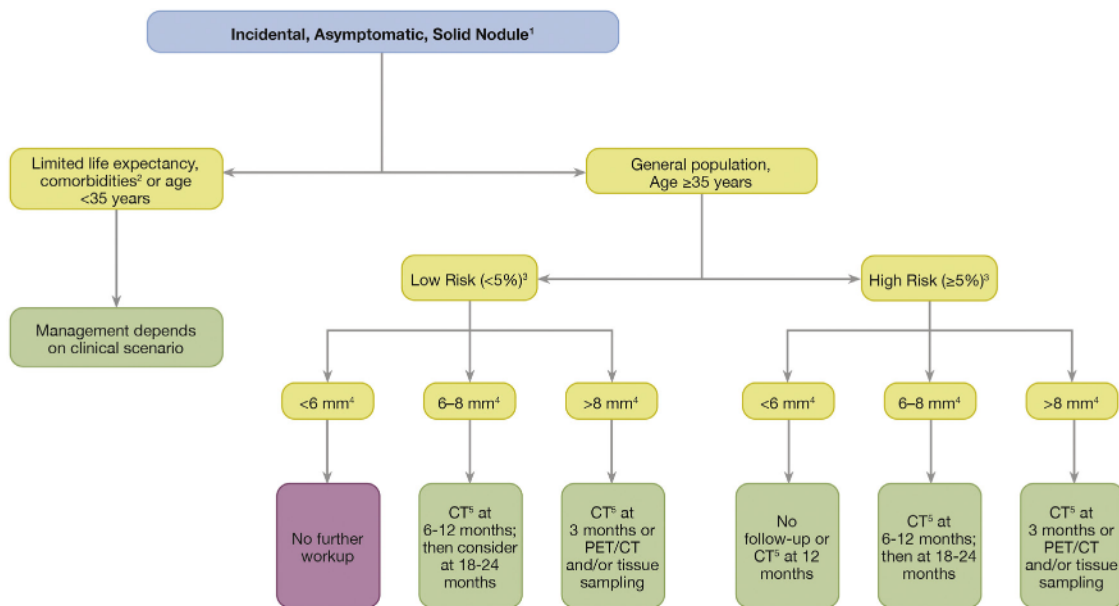
<sup>ii</sup>Associate Chair, Integrated Imaging & Imaging Sciences, MGH Radiology, Massachusetts General Hospital, Boston, Massachusetts.

<sup>jj</sup>Executive Director, Clinical Enterprise Integration, Mass General Brigham (MGB) Radiology, Massachusetts General Hospital, Boston, Massachusetts.

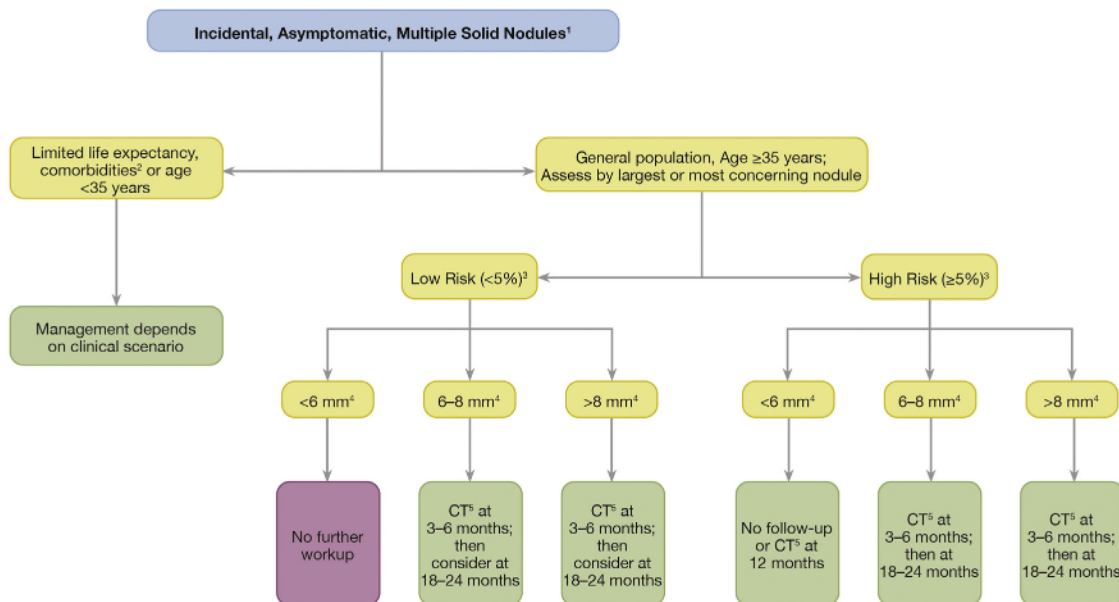
<sup>kk</sup>Associate Professor of Radiology, Massachusetts General Hospital, Harvard Medical School, Boston, Massachusetts.

Corresponding author and reprints: Reginald F. Munden, MD, DMD, MBA, Medical University of South Carolina, Department of Radiology, 96 Jonathan Lucas Street, MSC 323, Charleston, SC 29425.

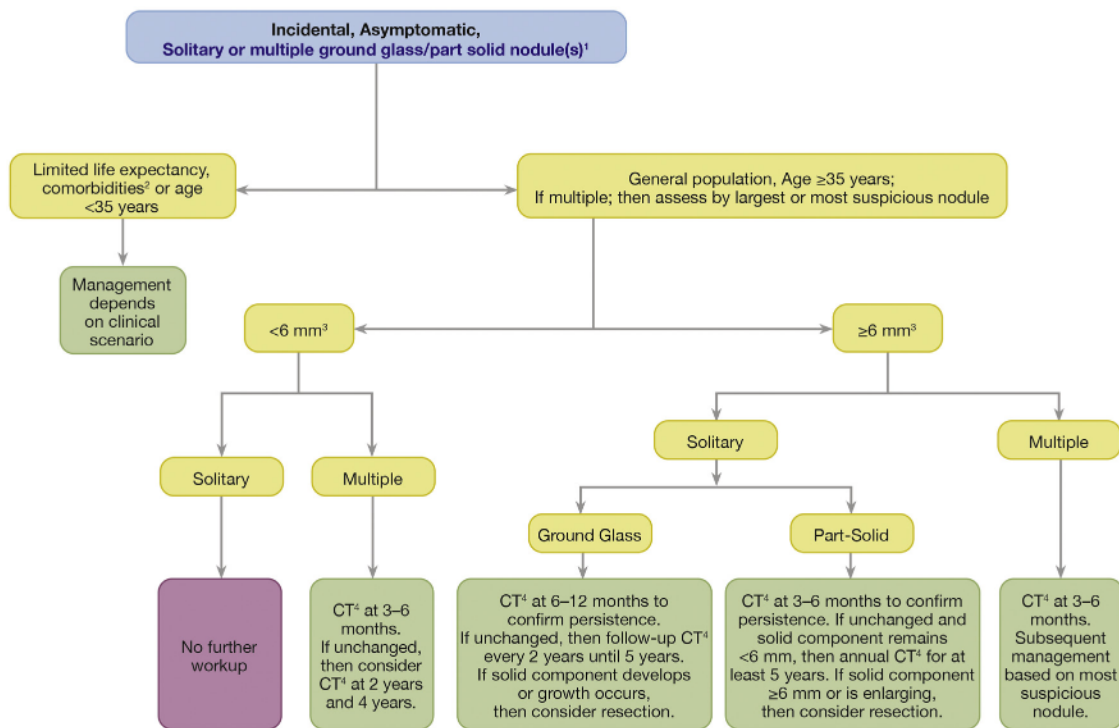
Dr Munden reports other from Optellum, other from TheraBionics, outside the submitted work. Dr MacMahon reports personal fees from Riverain Technology, other from Hologic, grants from Bioclinica, grants from Philips Healthcare, outside the submitted work. Dr Ko reports grants from Siemens Healthineers, outside the submitted work. Dr Naidich reports personal fees from PM-Google Radiology Consulting—CLST, personal fees from IC-Radiologist Board Certified by Vituity, Inc, outside the submitted work. Dr Rossi reports speaker: Boehringer Ingelheim. Dr McAdams reports personal fees from Novartis, non financial support from Pfizer, non financial support from Gilead Sciences, non financial support from Abbott Labs, non financial support from Amgen, non financial support from Johnson & Johnson, non financial support from Bristol-Myers-Squibb, outside the submitted work. Dr Berland reports personal fees from Nuance, Inc; personal fees from iMedis AI, Inc; personal fees from DeepSight Technologies, Inc; and personal fees from American Medical Foundation, outside the submitted work. Dr Pandharipande reports grants from Medical Imaging and Technology Alliance, outside the submitted work. The other authors state that they have no conflict of interest related to the material discussed in this article. Dr Rossi is a partner. Dr McAdams is a partner. Dr Berland is retired from practice. Dr Munden, Dr Black, Dr Hartman, Dr MacMahon, Dr Ko, Dr Dyer, Dr Naidich, Dr Goodman, Dr Brown, Dr Kent, Dr Carter, Dr Chiles, Dr Leung, Dr Boiselle, Dr Kazerooni, and Dr Pandharipande are faculty.



**Fig. 1.** Incidental, asymptomatic solid nodule. Flowchart for evaluation of an incidentally detected solid pulmonary nodule. (1) The recommendations are offered as general guidance and do not apply to all patients. (2) Limited life expectancy and comorbidities that increase the risk of treatment or are more likely to cause morbidity and mortality than the suspected lung cancer, given the nodule size. (3) Risk based on relevant patient risk factors as per Fleischner criteria. (4) Size in millimeters is defined as the average of long- and short-axis diameters, both of which should be obtained in the same transverse, coronal, or sagittal reconstructed images. (5) Chest CT should be noncontrast and use low-dose technique.



**Fig. 2.** Incidental, asymptomatic multiple solid nodules. Flowchart for incidentally detected multiple solid pulmonary nodules. (1) The recommendations are offered as general guidance and do not apply to all patients. (2) Limited life expectancy and comorbidities that increase the risk of treatment or are more likely to cause morbidity and mortality than the suspected lung cancer, given the nodule size. (3) Risk based on relevant patient risk factors as per Fleischner criteria. (4) Size in millimeters is defined as the average of long- and short-axis diameters, both of which should be obtained in the same transverse, coronal, or sagittal reconstructed images. (5) Chest CT should be noncontrast and use low-dose technique. Note: For multiple nodules, management is based on the largest or most concerning nodule.



**Fig. 3.** Incidental, asymptomatic solitary or multiple ground glass or part-solid nodule(s). Flowchart for incidentally detected solitary or multiple ground glass or part-solid pulmonary nodule(s). (1) The recommendations are offered as general guidance and do not apply to all patients. (2) Limited life expectancy and comorbidities that increase the risk of treatment or are more likely to cause morbidity and mortality than the suspected lung cancer, given the nodule size. (3) Size in millimeters is defined as the average of long- and short-axis diameters, both of which should be obtained in the same transverse, coronal, or sagittal reconstructed images. (4) Chest CT should be noncontrast and use low-dose technique. Note: For multiple nodules, management is based on the largest or most concerning nodule.

### ELEMENTS OF THE FLOWCHARTS: COLOR CODING

Algorithms for managing incidental findings are depicted in multiple flowcharts (Figs. 1-6). Within each flowchart, yellow boxes indicate using or acquiring clinical data (eg, lesion size), green boxes describe recommendations for action (eg, follow-up imaging), and red boxes indicate that workup or followup may be terminated (eg, if the finding is presumed to be benign). To minimize complexity, each algorithm addresses most—but not all—imaging appearances and clinical scenarios. Radiologists should feel comfortable deviating from the algorithm in circumstances that are not represented in the algorithm, based on the specific imaging appearance of the finding in question and patient characteristics—the algorithm content must be viewed as recommendations and should not be considered as “standard of care.”

### INCLUSION AND EXCLUSION CRITERIA

Patients for whom our recommendations are applicable include adults (≥35 years) who are asymptomatic and have undergone imaging for a reason unrelated to the incidental finding. The algorithm should not be applied if the patient

has signs or symptoms related to the incidental finding. Radiologists should use discretion when considering patients with limited life expectancy and substantial comorbidities; further downstream care should not be pursued if patients are unable to tolerate therapy or are unlikely to live long enough to incur potential harms of the incidental finding.

### IMAGING PROTOCOL OPTIMIZATION

In the discussion of the lung findings addressed in this article, comments apply to standard and low-dose examinations, whether performed with or without intravenous contrast. If relevant, those findings potentially affected by low-dose examinations are noted. All thoracic CT should be reconstructed into contiguous thin sections for viewing lung detail (eg, 1.0-1.5 mm) and thicker sections for overview of the lungs and soft tissues (eg, 2.0-3.0 mm).

### PART I: LUNG NODULES

#### Relevant Patient Populations

When considering management of incidental lung nodules, additional guidance concerning exclusion criteria is warranted, as detailed in the following four points. Importantly,

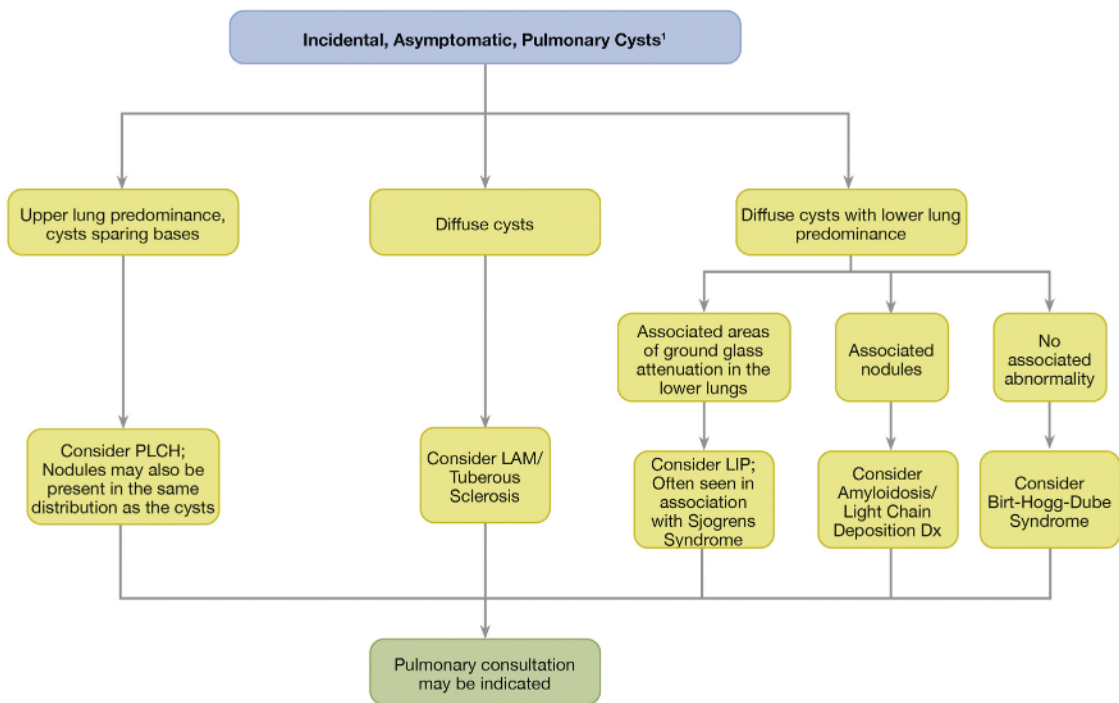


Fig. 4. Incidental, asymptomatic pulmonary cysts. Flowchart for evaluation of an incidentally detected pulmonary cyst(s). (1) The recommendations are offered as general guidance and do not apply to all patients. LAM = lymphangioleiomyomatosis; LIP = lymphoid interstitial pneumonia; PLCH = pulmonary Langerhans cell histiocytosis.

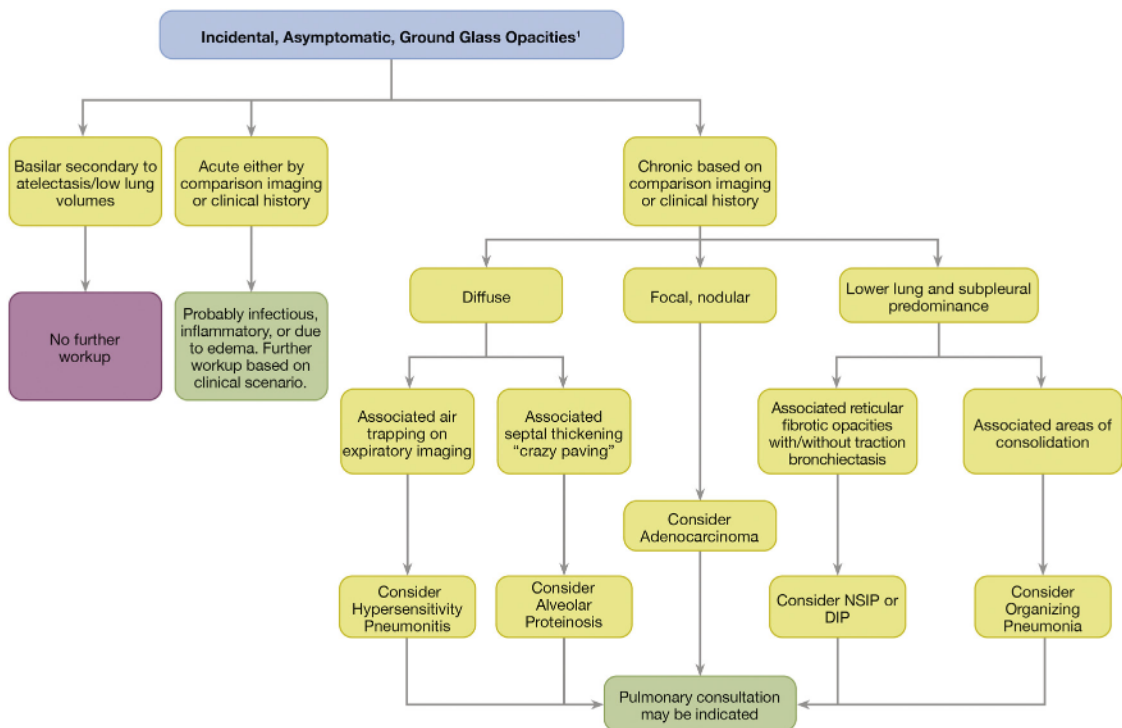
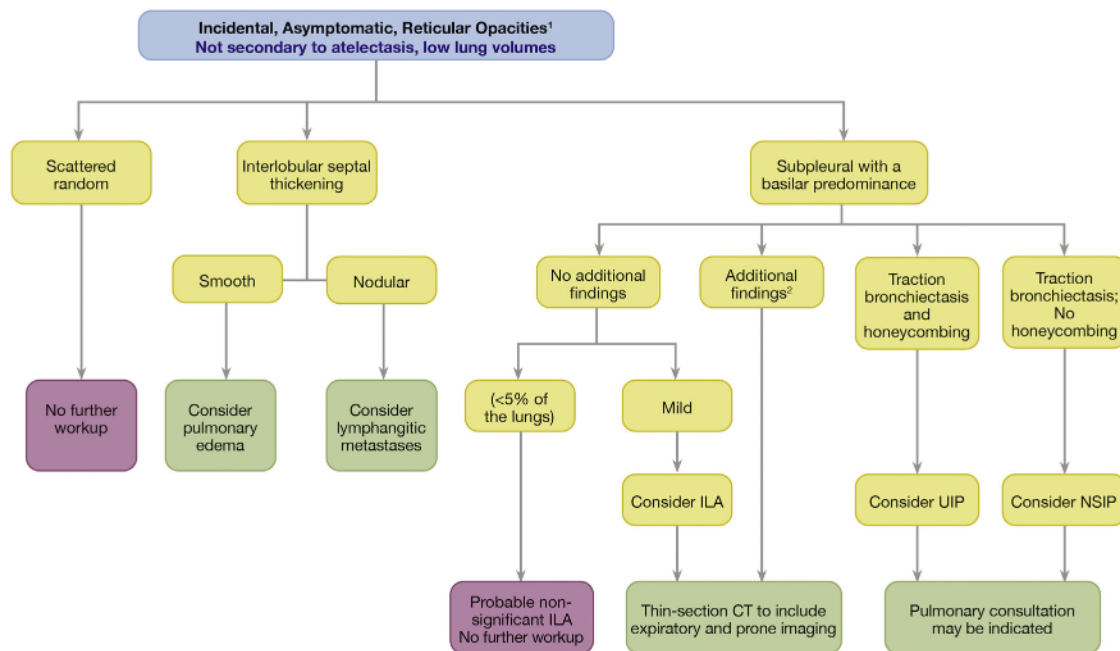


Fig. 5. Incidental, asymptomatic ground glass opacities. Flowchart for evaluation of incidentally detected ground glass opacities. (1) The recommendations are offered as general guidance and do not apply to all patients. DIP = desquamative interstitial pneumonia; NSIP = nonspecific interstitial pneumonia.



**Fig. 6.** Incidental, asymptomatic reticular opacities. Flowchart for evaluation of incidentally detected reticular opacities. 1) The recommendations are offered as general guidance and do not apply to all patients. (2) Additional findings such as diffuse nodules, predominant ground glass opacity, and cysts. ILA = interstitial lung abnormalities; NSIP = nonspecific interstitial pneumonia; UIP = usual interstitial pneumonia.

the ACR's IFC recommendations for incidental nodules closely follow those of Fleischner Society guidelines [3], providing clarification in specific domains.

Populations for which the IFC's recommendations should not be used include the following:

1. Recommendations do not apply for patients in a lung cancer screening program using Lung-RADS® or another appropriate classification and reporting system [4].
2. Recommendations are not for patients with a recent history of a malignancy. For those, when CT is performed outside the normal follow-up guidelines, the potential for metastatic disease should be raised. Management depends on consultation with the referring physician, primary tumor histology, risk of metastases or a new primary malignancy, or patient comorbidities. In general, a short-term followup (1-6 months depending on primary tumor histology) will provide some indication of metastatic potential [5,6].
3. Recommendations are not intended for nodule management in patients with unexplained fever or unexplained symptoms.
4. For all other scenarios, use of Fleischner Society guidelines [3] is advised. Examples of such scenarios include patients undergoing thoracic CT for cardiac evaluation, patients being evaluated for pulmonary embolus, and patients with remote history of cancer treatment (>5 years).

## Nature and Scope of the Problem

Pulmonary nodules are among the most common incidental finding on thoracic CT and are found in about 50% of smokers over the age of 50 years [7]. Overall, the probability of malignancy in an incidental pulmonary nodule is very low but is highly dependent on nodule size and other characteristics of the nodule and patient [8]. Guidelines for incidental noncalcified solid and part-solid nodules were originally published by the Fleischner Society in 2005 [9] for solid nodules and in 2013 [10] for part-solid nodules. A more recent update by the Fleischner Society for all nodules was published 2017 [3]. This section will not duplicate the recent 2017 Fleischner revision [3] but will highlight recent changes since the publications and address a few additional considerations.

## Reporting Considerations

**Overview.** A pulmonary nodule is a rounded opacity, well or poorly defined, measuring up to 3 cm in diameter [11]. A solid nodule has homogenous soft-tissue attenuation. A pure ground glass or nonsolid nodule has hazy, increased attenuation of the lung parenchyma that does not obliterate bronchial and vascular margins. A part-solid nodule consists of both ground glass and solid soft-tissue attenuation.

The majority of nodules are benign with the risk of malignancy primarily related to size and patient risk factors

[7,8,12]. Although there is overlap in the differential of solitary versus multiple pulmonary nodules, this distinction may have diagnostic implications. For instance, the malignancy of consideration for a solitary nodule is primary lung cancer, whereas for multiple nodules it is metastases.

The following elements should be considered when reporting an incidental nodule detected on CT:

1. Size (average diameter) in mm
2. Number (solitary or multiple)
3. Density (solid, part-solid, nonsolid, presence and pattern of calcification, presence of fat)
4. Morphology
5. Location and relationship to pleura

**1 Size** Pulmonary nodule size, defined as the average (rounded to the nearest millimeter) of the long- and short-axis diameters, should be measured on lung rather than mediastinal windows [13]. Diameters should be obtained using thin ( $\leq 1.5$  mm) section images with electronic calipers. Alternatively, size may be assessed using volumetric analysis software, which is more reproducible than manual measurements [13,14]. For part-solid nodules, the size of the solid component should be measured on lung windows. Nodules that have clearly benign characteristics (as determined by density or morphology) do not require measurement.

**2 Number** The presence of single versus multiple lung nodules should be reported.

**3 Density** Nodule density is classified as solid, part-solid, or ground glass. Solid nodule density should be assessed using mediastinal windows reconstructed with standard algorithms because sharp reconstruction algorithms (including lung settings) cause artifacts that simulate or obscure calcification resulting in erroneous Hounsfield Unit measurements [15]. For smoothly marginated nodules, the following patterns of calcification reliably exclude malignancy: central nidus comprising a majority of the nodule, laminated, popcorn, and diffuse [16]. Focal fat attenuation ( $-120$  to  $-40$  Hounsfield Units) in a smoothly marginated nodule is a reliable sign of a hamartoma in patients without prior malignancy [17]. Part-solid nodules and ground glass nodules are based on the presence of (part-solid) or lack of a solid component (ground glass). The maximum dimension of the solid component within a part-solid nodule should be noted.

**5 Morphology** The margin characteristics of lung nodules should be reported: smooth, spiculated, or lobulated. For any nodule, a spiculated or lobulated margin versus a smooth margin increases the risk of primary lung cancer by a factor of about two [8]. Irregular apical opacities are very common in

patients over 50 years of age and are almost always due to bronchiolitis. However, coronal and sagittal reformations can often be helpful in distinguishing malignancy, which usually manifests as a discrete nodule or mass, from bronchiolitis, which originates from the pleura and has concave margins.

**6 Location and Relationship to the Pleura** A nodule's location and relationship to the pleura should be reported. A "perisubpleural nodule" is a perisubpleural or juxtapleural homogeneous, solid nodule that has smooth margins and an oval, lentiform, or triangular shape [18]. They represent about 20% of nodules detected in lung cancer screening and are usually caused by benign intrapulmonary lymph nodes [16,18]. Benign intrapulmonary lymph nodes also may present as juxtapleural nodules [19]. Follow-up CT is not recommended for either perisubpleural or juxtapleural nodules with typical benign or lymph node morphology, when their size is  $\leq 10$  mm.

**Additional Considerations.** Additional thoracic CT findings such as enlarged lymph nodes, presence of a pleural effusion, and abnormalities of the upper abdomen (eg, liver lesions) may be important when managing an incidentally detected pulmonary nodule as this may indicate a higher probability for malignancy of the nodule. Comparisons to prior imaging should be made whenever possible. In general, before an invasive intervention, follow-up CT should be strongly considered.

## Implications of Imaging and Clinical Features

### Common Principles of Our Algorithm (Figs. 1-3).

1. Size is the primary determinant of management and risk of malignancy.
2. Density is an important determinant of malignancy risk. Pure ground glass nodules have a low malignancy rate, and part-solid nodules or development of a solid component within a pure ground glass nodule is concerning for malignancy.
3. Longitudinal assessment is commonly needed for characterization.

**Revised Fleischner Society Guidelines [3].** For *solitary solid nodules*, the major changes since 2005 [3,9] have been the following (Table 1):

1. Increase in size threshold for follow-up in low-risk population to 6 mm
2. Optional followup in high-risk population for nodules  $\geq 6$  mm
3. Increased emphasis on nodule morphology and location for management decisions

**Table 1.** Revised Fleischner 2017 guidelines for management of incidentally detected nodules in adults. A: Solid Nodules\* B: Subsolid Nodules\*

**A: Solid Nodules\***

Nodule Type	Size			Comments
	6 mm (100 mm <sup>3</sup> )	6-8 mm (100-250 mm <sup>3</sup> )	>8 mm (>250 mm <sup>3</sup> )	
<b>Single</b>				
Low risk <sup>†</sup>	No routine followup	CT at 6-12 months, then consider CT at 18-24 months	Consider CT at 3 months, PET/CT or tissue sampling	Nodules <6 mm do not require routine followup in low-risk patients (recommendation 1A)
High risk <sup>†</sup>	Optional CT at 12 mo	CT at 6-12 mo, then CT at 18-24 mo	Consider CT at 3 mo, PET/CT, or tissue sampling	Certain patients at high risk with suspicious nodule morphology, upper lobe location, or both may warrant 12-mo followup (recommendation 1A).
<b>Multiple</b>				
Low risk <sup>†</sup>	No routine followup	CT at 3-6 mo, then consider CT at 18-24 mo	CT at 3-6 mo, then consider CT at 18-24 mo	Use most suspicious nodule as guide to management; followup intervals may vary according to size and risk (recommendation 2A).
High risk <sup>†</sup>	Optional CT at 12 months	CT at 3-6 months, then at 18-24 months	CT at 3-6 months, then at 18-24	Use most suspicious nodule as guide to months management; followup intervals may vary according to size and risk (recommendation 2A).

**B: Subsolid Nodules\***

Nodule Type	Size		Comments
	6 mm (100 mm <sup>3</sup> )	≥6 mm (≥100 mm <sup>3</sup> )	
<b>Single</b>			
Ground glass	No routine followup	CT at 6-12 mo to confirm persistence, then CT every 2 y until 5 y	For certain suspicious nodules <6 mm, consider follow-up at 2 y and 4 y; if solid component(s) develops or growth occurs, consider resection (recommendations 3A and 4A).
Part solid	No routine followup	CT at 3-6 mo to confirm persistence; if unchanged and solid component remains <6 mm, annual CT should be performed for 5 y.	In practice, part-solid nodules cannot be defined as such until they are ≥6 mm, and nodules <6 mm usually do not require follow-up; persistent part-solid nodules with a solid components ≥6 mm should be considered highly suspicious (recommendations 4A-4C)
Multiple	CT at 3-6 mo; if stable, consider CT at 2 and 4 y.	CT at 3-6 mo; subsequent management based on the most suspicious nodule(s).	Multiple <6 mm pure ground-glass nodules are usually benign, but consider follow-up at 2 y and 4 y in selected patients at high risk (recommendation 5A).

These recommendations do not apply to lung cancer screening, patients with immunosuppression, or patients with known primary cancer.

\*Dimensions are average of long and short axes, rounded to the nearest millimeter.

<sup>†</sup>Consider all relevant risk factors (see Risk Factors).



For solitary pure ground glass nodules, the major changes since 2013 [10] have been the following (Table 1, Fig. 3):

1. For nodules  $\geq 6$  mm, prolong initial follow-up interval from 3 months to 6 to 12 months.
2. Prolong subsequent follow-up interval from 1 year to 2 years, with followup until 5 years after the initial detection.

For solitary part-solid nodules, major changes since 2013 [10] have been the following (Table 1, Fig. 3):

1. For nodules  $\geq 6$  mm, an option to delay initial followup from 3 months to 6 months
2. If no change on initial followup and solid component  $\geq 6$  mm, then continue annual CT for at least 5 years
3. If solid component  $\geq 6$  mm or enlarging, consider resection

For multiple solid and part-solid nodules, management is based on the largest or most suspicious nodule but generally with an earlier initial followup than for single nodules of a similar size (Table 1, Figs. 2 and 3).

Other changes to the Fleischner Society guidelines [3] include a greater emphasis on nodule morphology and a redefinition of low-risk ( $< 5$ ) and high-risk ( $\geq 5$ ) categories in accordance with the proposal by the American College of Chest Physicians [20]. We agree with the American College of Chest Physicians proposal that the risk of lung cancer is best estimated with a validated prediction model, such as the Vancouver (PanCan) risk model [8], which is the only validated model for CT detection. Because the model was developed from a high-risk population with a heavy smoking history, it is useful for providing an upper limit on the probability of lung cancer. The full model includes four patient risk factors (age, sex, family history of lung cancer, and emphysema) and five nodule risk factors—size (maximum diameter), nodule count, density (solid, part-solid, nonsolid), location, spiculation. For comparison, Fleischner criteria employ a modified version of risk categories proposed by the American College of Chest Physicians [20], which is low risk ( $< 5$  malignancy risk) and high risk ( $\geq 5$ ). Low risk is associated with young age, less smoking, smaller nodule size, regular margins, and location in an area other than the upper lobe. High risk is associated with older age, heavy smoking, larger nodule size, irregular or spiculated margins, and upper lobe location [3].

Despite the fact that the PanCan model assumes a high-risk smoking population, the model categorizes most patients with nodules  $\leq 6$  mm in maximum diameter as low risk. Thus, it is reasonable to consider all patients with nodules  $\leq 6$  mm as low risk unless all

other risk factors are positive. Of note, although the PanCan model provides the best estimate of risk in small nodules detected incidentally with thoracic CT, the model does not perform as well for nodules larger than 10 mm [21].

## PART II: OTHER LUNG FINDINGS

### Pulmonary Cyst

**Nature and Scope of the Problem.** A pulmonary cyst is a region of low attenuation within the lung parenchyma with a wall that creates a well-defined interface with normal lung on thoracic CT [11]. Pulmonary cysts are common and likely related to aging. In one study, asymptomatic cysts were reported in 25% of patients older than 75 years and none in patients younger than 55 years [22]. Winter et al reported pulmonary cysts in 13% of patients older than 65 years but none in those 30 to 50 years old [23]. In the Framingham Heart Study, pulmonary cysts were seen in 7.6% of the population [24] with none present in patients less than 40 years old [24]. Isolated thin wall solitary cysts are usually the result of infection or inflammatory processes and are benign. Thick wall ( $>2$  mm) cysts may require further evaluation. A cyst associated with a nodular component either in the wall or abutting the cyst should be followed because of the association of cystic lung cancer [25-28]. Sheard et al have proposed a classification system for cystic lung cancers [28]: Type I represents a nodule outside the cystic air space and abutting the wall. Type II is that of a nodule projecting into the cystic air space from the wall. Type III is that of cyst wall thickening, which may not necessarily be circumferential, without an area of focal nodularity. Type IV is a multicystic lesion.

Emphysematous changes can usually be easily distinguished from cystic lung disease unless the cystic lung disease is mild. The absence of a defined wall and presence of central linear or nodular opacities within the areas of air attenuation are the most helpful findings for identification of emphysema. Because emphysema is the result of destruction of the lung parenchyma, it will present on CT images as areas of decreased attenuation (air) without a defined wall; the centrilobular core structures (bronchial artery, bronchiole, and intralobular septa) are spared, resulting in linear and nodular opacities within the areas of air attenuation. Of note, if the destruction extends to the interlobular septa, then the alveolar destruction may mimic a cyst by the pseudo-wall appearance. This is in contradistinction to cystic lung diseases, which tend to displace the centrilobular core structures along the peripheral wall of the area of air attenuation of the cyst [29].

The two most commonly encountered cystic lung diseases on thoracic CT are lymphangiomyomatosis and pulmonary Langerhans cell histiocytosis. Cystic lung disease also may be seen in a number of additional diseases including Birt-Hogg-Dube syndrome, lymphocytic interstitial pneumonitis, and amyloidosis. Finally, although not true cystic lung diseases, fibrotic interstitial lung diseases that result in honeycombing (subpleural clusters or rows of cysts) can present with associated cystic changes in the lungs. Usual interstitial pneumonitis (UIP) is the most common cause, although nonspecific interstitial pneumonitis (NSIP), desquamative interstitial pneumonitis, chronic hypersensitivity pneumonitis, and sarcoidosis also can have mild honeycombing present.

The distribution of the cysts and associated findings are the two most important considerations in the evaluation of cystic lung disease. The cysts may be diffuse or may have upper or lower lung predominance. Associated findings that may be helpful in the differential diagnosis include pulmonary nodules and areas of ground glass attenuation.

**Reporting Considerations.** The following elements should be considered when reporting an incidentally detected pulmonary cyst.

1. Presence or absence of a wall
2. Wall thickness (thin or thick)
3. Single versus multiple
4. Distribution

**Implications of Imaging and Clinical Features.** The incidental findings algorithm for pulmonary cysts is shown in Fig. 4. Common principles include:

1. Cysts with perceptible walls should be further evaluated with regard to distribution of the cysts, associated findings, clinical correlation, and remote imaging to determine if clinically significant.
2. Emphysema is common in the appropriate clinical setting and easily recognized by cysts without defined walls. The type (centrilobular or paraseptal) and extent should be noted.

## Ground Glass Opacity

**Nature and Scope of the Problem.** Ground glass opacity is defined as hazy increased opacity of the lung with preservation of bronchial and vascular margins; it is differentiated from consolidation, which is defined as a homogeneous increase in lung attenuation that obscures vessels and airway

walls [11]. Ground glass opacities may result from a wide spectrum of diseases that partially fill the air spaces, result in interstitial thickening, or a combination of both. Given the broad differential diagnosis, clinical information is critical in the determination of etiology. Separation of the extent of ground glass opacification as diffuse or focal and localized is also useful [30].

Considerations for diffuse ground glass opacities include infections, pulmonary edema, diffuse alveolar hemorrhage, drug toxicity, interstitial pneumonias, or diffuse lung diseases, including cellular NSIP, hypersensitivity pneumonitis, desquamative interstitial pneumonitis, cryptogenic organizing pneumonia, sarcoidosis, and subacute diffuse alveolar damage [31]. Ground glass opacities in combination with interlobular septal thickening may result in a crazy-paving appearance. Although initially described in pulmonary alveolar proteinosis, the appearance is not pathognomonic and may be seen in pulmonary edema, hemorrhage, infection, sarcoidosis, lipoid pneumonia, and adenocarcinoma [31,32]. As most diffuse lung diseases are not homogeneous but show patchy differences in lung attenuation, diffuse lung disease can usually be differentiated from the normal appearance of lungs on an expiratory CT scan [31]. Regional differences in blood flow in patients with obstructive pulmonary disease may result in regions of mosaic attenuation between the involved lung and the relatively normal lung [33]. Similarly, chronic thromboembolic disease may result in regions of mosaic oligemia in some regions and increase in blood flow in other regions in which the arterial bed remains patent, resulting in mosaic attenuation of the lung parenchyma. Mosaic attenuation from whatever cause can be differentiated from other causes of ground glass attenuation by observing the size of the centrilobular vessels in the areas of higher and lower attenuation. If the cause of the mixed attenuation is due to fluid or cellular infiltration, then the vessel size between the areas of high attenuation and low attenuation will be similar. If the cause of the mixed attenuation is due to an airway or vascular abnormality, the vessel size in the areas of low attenuation will be smaller than in the areas of high attenuation (mosaic oligemia).

Expiratory imaging can be helpful to differentiate between primary vascular causes of mosaic oligemia such as chronic thromboembolic disease and secondary causes due to small airways disease. Small airways disease will show air trapping on expiratory imaging, and air trapping is not typically present with a primary vascular cause.

Focal or nodular ground glass opacities may be seen in primary lung adenocarcinoma in situ and minimally invasive

adenocarcinoma, as well as benign conditions such as infection, inflammation, pulmonary hemorrhage, and focal interstitial fibrosis [34]. Workup of these focal ground glass opacities discovered incidentally is covered in the section of nodules.

**Reporting Considerations.** The following elements should be considered when reporting incidentally detected ground glass opacities:

1. Acute or chronic
2. Diffuse or focal
3. Distribution—upper versus lower lung and central, subpleural, or random
4. Associated findings—reticular opacities, cardiomegaly, pleural effusions

**Implications of Imaging and Clinical Features.** The incidental findings algorithm for ground glass opacities is shown in Fig. 5. Common principles include the following:

1. Acute versus chronic is a primary determinant of etiology.
2. Distribution and extent are useful for limiting differential.
3. Associated findings may determine cause.

## Interlobular Septal Thickening and Reticular Opacities

**Nature and Scope of the Problem.** Interlobular septal thickening involves thickening of the interlobular septa, which contain the pulmonary veins and lymphatics. Septal thickening outlines the polygonal structure of the secondary pulmonary lobule. Smooth, bilateral septal thickening is frequently due to pulmonary edema. Associated findings include peribronchial thickening, subpleural thickening, and pleural effusion. Lymphangitic carcinomatosis also thickens the interlobular septa, which can be nodular or smooth and is usually seen in the setting of a known malignancy, especially breast, lung, colon, and gastric cancer. Irregular interlobular septal thickening in sarcoidosis is not typically the predominant finding and is frequently associated with the predominant finding of perilymphatic nodules. Follow-up imaging of interlobular septal thickening is performed as clinically indicated.

Reticular opacities are due to infiltration and thickening of the interstitial framework of the secondary pulmonary lobule. Reticular opacities represent a mesh-like network of fine lines that do not conform to lobular anatomy. The network of fine lines may be a combination of the following: interlobular septal thickening, intra-lobular septal thickening, peribronchovascular interstitial thickening, traction bronchiectasis, and honeycombing. The pattern and distribution of reticular opacities and

presence of associated findings can help identify the pathologic type of fibrosis.

Two important pathologic types of fibrosing interstitial pneumonia are UIP and NSIP. These entities have characteristic patterns on high-resolution chest CT. Reticular opacities are present in both UIP and NSIP. UIP pattern is typically peripheral and basilar. Recent revisions in the classification schema by the Fleischner Society for UIP outlines patterns as typical UIP, probable UIP, indeterminate for UIP, and alternate diagnosis [35,36]. In the UIP pattern, traction bronchiectasis (dilatation and distortion of bronchi and bronchioles) is present within areas of fibrosis, and there is associated honeycombing. The NSIP pattern is also basilar predominant and demonstrates traction bronchiectasis. There is typically no honeycombing in NSIP. Subpleural sparing may be identified in areas of NSIP [37] and can be used to differentiate NSIP from UIP when it is present.

Reticular opacities suggesting interstitial lung abnormalities, defined as more than 5% of the lungs [38], are reported in 7% to 11% of the elderly [39]. In asymptomatic patients, these have been thought to represent benign findings [22,40]. More recent investigations indicate these opacities can progress and are associated with increased risk of mortality [41,42] and posttherapy complications [43-47]. Therefore, the presence and distribution of reticular opacities is important, and if patients become symptomatic, then follow-up imaging or consultation may be warranted.

The combination of reticular opacities in the setting of emphysema has been classified as combined pulmonary fibrosis and emphysema. Although this classification has some clinical utility, it is uncertain as to whether it represents a distinct entity [48,49].

Focal reticular opacities in the medial right lower lobe adjacent to a prominent osteophyte of the thoracic spine are usually due to scarring. These are not clinically significant and require no further follow-up [50]. Dependent bilateral lower lobe opacity may or may not be significant. Such opacity may simply represent gravity-dependent atelectasis or can be artifactual and exaggerated by the presence of intravenous contrast and typically requires no further imaging follow-up. However, in a patient with persistent unexplained dyspnea and dependent reticular opacities, a high-resolution chest CT with prone imaging is recommended.

Management of incidental interstitial opacities on routine chest CT can be problematic. The opacities may be artifactual, represent scarring, or true fibrosis. High-resolution chest CT of the thoracic is recommended to confirm or further characterize the abnormalities.

## Reporting Considerations

The following elements should be considered when reporting incidentally detected interlobular thickening or reticular opacities:

1. Distribution
2. Associated findings

## Implications of Imaging and Clinical Features

The incidental findings algorithm for reticular opacities is shown in [Figure 6](#). Common principles include the following:

1. Distribution may influence the differential diagnosis.
2. Associated findings may influence the differential diagnosis.

### TAKE-HOME POINTS

We propose algorithms for managing incidental pulmonary findings, including lung nodules, pulmonary cysts, ground glass opacities, and interlobular septal thickening and reticular opacities.

Pulmonary nodule(s) management centers on the risk of malignancy, which is primarily related to size, density, morphology, and patient risk factors.

Pulmonary cysts are common and mostly benign but evaluation depends upon wall thickness and distribution within the lungs.

Ground glass opacities are secondary to a variety of diseases and are evaluated based on acuity or chronicity, extent of lungs involved, distribution, and associated findings.

Interlobular septal thickening and reticular opacities are assessed by distribution within the lungs and associated findings.

All pulmonary incidental findings are best managed in a shared decision process between the radiologists, referring or consulting physician, and the patient.

## ADDITIONAL RESOURCES

Additional resources can be found online at: <https://doi.org/10.1016/j.jacr.2021.04.014>.

## REFERENCES

1. Munden RF, Chiles C, Boiselle PM, Sicks JD, Aberle DR, Gatsonis CA. Micronodules detected on CT during the NLST: prevalence and relation to positive studies and lung cancer. *J Thorac Oncol* 2019;14(9):1538-46. <https://doi.org/10.1016>
2. Berland LL, Silverman SG, Gore RM, et al. Managing incidental findings on abdominal CT: white paper of the ACR incidental findings committee. *J Am C Radiol* 2010;7:754-73.
3. MacMahon H, Naidich DP, Goo JM, et al. Guidelines for management of incidental pulmonary nodules detected on CT images: from the Fleischner Society 2017. *Radiology* 2017;284:228-43.
4. CMS. Decision memo for screening for lung cancer with low dose computed tomography (LDCT). Available at: <https://www.cms.gov/medicare-coverage-database/details/nca-decision-memo.aspx?NCAId=274>. Accessed January 7, 2021.
5. Munden RF, Erasmus JJ, Wahba H, Fineberg NS. Follow-up of small (4 mm or less) incidentally detected nodules by computed tomography in oncology patients: a retrospective review. *J Thorac Oncol* 2010;5:1958-62.
6. Munden RF, Pugatch RD, Liptay MJ, Sugarbaker DJ, Le LU. Small pulmonary lesions detected at CT: clinical importance. *Radiology* 1997;202:105-10.
7. Swensen SJ, Silverstein MD, Ilstrup DM, Schleck CD, Edell ES. The probability of malignancy in solitary pulmonary nodules. Application to small radiologically indeterminate nodules. *Arch Intern Med* 1997;157:849-55.
8. McWilliams A, Tammemagi MC, Mayo JR, et al. Probability of cancer in pulmonary nodules detected on first screening CT. *N Engl J Med* 2013;369:910-9.
9. MacMahon H, Austin JH, Gamsu G, et al. Guidelines for management of small pulmonary nodules detected on CT scans: a statement from the Fleischner Society. *Radiology* 2005;237:395-400.
10. Naidich DP, Bankier AA, MacMahon H, et al. Recommendations for the management of subsolid pulmonary nodules detected at CT: a statement from the Fleischner Society. *Radiology* 2013;266:304-17.
11. Hansell DM, Bankier AA, MacMahon H, McLoud TC, Muller NL, Remy J. Fleischner Society: glossary of terms for thoracic imaging. *Radiology* 2008;246:697-722.
12. Gould MK, Ananth L, Barnett PG, Veterans Affairs SCSG. A clinical model to estimate the pretest probability of lung cancer in patients with solitary pulmonary nodules. *Chest* 2007;131:383-8.
13. Bankier AA, MacMahon H, Goo JM, Rubin GD, Schaefer-Prokop CM, Naidich DP. Recommendations for measuring pulmonary nodules at CT: a statement from the Fleischner Society. *Radiology* 2017;285(2):584-600.
14. Zhao B, James LP, Moskowitz CS, et al. Evaluating variability in tumor measurements from same-day repeat CT scans of patients with non-small cell lung cancer. *Radiology* 2009;252:263-72.
15. Swensen SJ, Morin RL, Aughenbaugh GL, Leimer DW. CT reconstruction algorithm selection in the evaluation of solitary pulmonary nodules. *J Comput Assist Tomogr* 1995;19:932-5.
16. Collins J, Sterns EJ. Solitary and multiple pulmonary nodules. 3rd ed. Philadelphia, PA: Wolters Kluwer; 2015.
17. Siegelman SS, Khouri NF, Scott WW, Leo FP, Hamper UM, Fishman EK, et al. Pulmonary hamartoma: CT findings. *Radiology* 1986;160:313-7.
18. de Hoop B, van Ginneken B, Gietema H, Prokop M. Pulmonary perisubpleural nodules on CT scans: rapid growth is not a predictor of malignancy. *Radiology* 2012;265:611-6.
19. Xu DM, van der Zaag-Loonen HJ, Oudkerk M, et al. Smooth or attached solid indeterminate nodules detected at baseline CT screening in the NELSON study: cancer risk during 1 year of follow-up. *Radiology* 2009;250:264-72.
20. Gould MK, Donington J, Lynch WR, et al. Evaluation of individuals with pulmonary nodules: when is it lung cancer? Diagnosis and management of lung cancer, 3rd ed: American College of Chest Physicians evidence-based clinical practice guidelines. *Chest* 2013;143:e93S-120S.
21. Hammer MM, Nachiappan AC, Barbosa EJM Jr. Limited utility of pulmonary nodule risk calculators for managing large nodules. *Curr Probl Diagn Radiol* 2018;47:23-7.

22. Copley SJ, Wells AU, Hawtin KE, et al. Lung morphology in the elderly: comparative CT study of subjects over 75 years old versus those under 55 years old. *Radiology* 2009;251:566-73.
23. Winter DH, Manzini M, Salge JM, et al. Aging of the lungs in asymptomatic lifelong nonsmokers: findings on HRCT. *Lung* 2015;193:283-90.
24. Araki T, Nishino M, Gao W, et al. Pulmonary cysts identified on chest CT: are they part of aging change or of clinical significance? *Thorax* 2015;70:1156-62.
25. Deng H, Zhang J, Zhao S, et al. Thin-wall cystic lung cancer: a study of 45 cases. *Oncol Lett* 2018;16:755-60.
26. Maki D, Takahashi M, Murata K, Sawai S, Fujino S, Inoue S. Computed tomography appearances of bronchogenic carcinoma associated with bullous lung disease. *J Comput Assist Tomogr* 2006;30:447-52.
27. Mascalchi M, Attina D, Bertelli E, et al. Lung cancer associated with cystic airspaces. *J Comput Assist Tomogr* 2015;39:102-8.
28. Sheard S, Moser J, Sayer C, Stefanidis K, Devaraj A, Vlahos I. Lung cancers associated with cystic airspaces: underrecognized features of early disease. *Radiographics* 2018;38:704-17.
29. Bonelli FS, Hartman TE, Swensen SJ, Sherrick A. Accuracy of high-resolution CT in diagnosing lung diseases. *AJR Am J Roentgenol* 1998;170:1507-12.
30. Miller WT Jr, Shah RM. Isolated diffuse ground-glass opacity in thoracic CT: causes and clinical presentations. *AJR Am J Roentgenol* 2005;184:613-22.
31. Hansell DM. Thin-section CT of the lungs: the hinterland of normal. *Radiology* 2010;256:695-711.
32. Walker CM, Abbott GF, Greene RE, Shepard JA, Vummidi D, Digumarthy SR. Imaging pulmonary infection: classic signs and patterns. *AJR Am J Roentgenol* 2014;202:479-92.
33. Remy-Jardin M, Remy J, Giraud F, Wattinne L, Gosselin B. Computed tomography assessment of ground-glass opacity: semiology and significance. *J Thorac Imaging* 1993;8:249-64.
34. Park CM, Goo JM, Lee HJ, Lee CH, Chun EJ, Im JG. Nodular ground-glass opacity at thin-section CT: histologic correlation and evaluation of change at follow-up. *Radiographics* 2007;27:391-408.
35. Lynch DA, Sverzellati N, Travis WD, et al. Diagnostic criteria for idiopathic pulmonary fibrosis: a Fleischner Society White Paper. *Lancet Respir Med* 2018;6:138-53.
36. Raghu G, Remy-Jardin M, Myers JL, et al. Diagnosis of idiopathic pulmonary fibrosis. An official ATS/ERS/JRS/ALAT clinical practice guideline. *Am J Respir Crit Care Med* 2018;198:e44-68.
37. Hodnett PA, Naidich DP. Fibrosing interstitial lung disease. A practical high-resolution computed tomography-based approach to diagnosis and management and a review of the literature. *Am J Respir Crit Care Med* 2013;188:141-9.
38. Hatabu H, Hunninghake GM, Lynch DA. Interstitial lung abnormality: recognition and perspectives. *Radiology* 2019;291:1-3.
39. Jin GY, Lynch D, Chawla A, et al. Interstitial lung abnormalities in a CT lung cancer screening population: prevalence and progression rate. *Radiology* 2013;268:563-71.
40. Oldham JM, Adegunsoye A, Khera S, et al. Underreporting of interstitial lung abnormalities on lung cancer screening computed tomography. *Ann Am Thorac Soc* 2018;15:764-6.
41. Araki T, Putman RK, Hatabu H, et al. Development and progression of interstitial lung abnormalities in the Framingham Heart Study. *Am J Respir Crit Care Med* 2016;194:1514-22.
42. Putman RK, Hatabu H, Araki T, et al. Association between interstitial lung abnormalities and all-cause mortality. *JAMA* 2016;315:672-81.
43. Im Y, Park HY, Shin S, et al. Prevalence of and risk factors for pulmonary complications after curative resection in otherwise healthy elderly patients with early stage lung cancer. *Respir Res* 2019;20:136.
44. Iwasawa T, Okudela K, Takemura T, et al. Computer-aided quantification of pulmonary fibrosis in patients with lung cancer: relationship to disease-free survival. *Radiology* 2019;292:489-98.
45. Yamaguchi S, Ohguri T, Ide S, et al. Stereotactic body radiotherapy for lung tumors in patients with subclinical interstitial lung disease: the potential risk of extensive radiation pneumonitis. *Lung Cancer* 2013;82:260-5.
46. Li F, Zhou Z, Wu A, et al. Preexisting radiological interstitial lung abnormalities are a risk factor for severe radiation pneumonitis in patients with small-cell lung cancer after thoracic radiation therapy. *Radiat Oncol* 2018;13:82.
47. Nakanishi Y, Masuda T, Yamaguchi K, et al. Pre-existing interstitial lung abnormalities are risk factors for immune checkpoint inhibitor-induced interstitial lung disease in non-small cell lung cancer. *Respir Investig* 2019;57:451-9.
48. Cottin V. Combined pulmonary fibrosis and emphysema: bad and ugly all the same? *Eur Respir J* 2017;50:1-4.
49. Antoniou KM, Margaritopoulos GA, Goh NS, et al. Combined pulmonary fibrosis and emphysema in scleroderma-related lung disease has a major confounding effect on lung physiology and screening for pulmonary hypertension. *Arthritis Rheumatol* 2016;68:1004-12.
50. Otake S, Takahashi M, Ishigaki T. Focal pulmonary interstitial opacities adjacent to thoracic spine osteophytes. *AJR Am J Roentgenol* 2002;179:893-6.